



PATIENT

Sparky Helliwell

SPECIES

Canine

BREED

Border Collie Mix

SEX

MN

AGE

10yr

WEIGHT

42.5

INTERPRETED BY

R. McKenzie Daniel,
DVM, DABVP
(Canine and Feline)

IMAGING PERFORMED BY

Sarah Green

HOSPITAL NAME

Healing Spirit Animal
Wellness

REFERRING VET

Sarah Green

INVOICE 24583

DATE

04/22/2026

PRESENTING CLINICAL SIGNS

History of intestinal resection/ anastomosis performed 8/23/25 to resection an iliocolic mass. IHC confirmed a GIST.

Recent intermittent diarrhea, appears to be improving with microbiome restorative therapy. Otherwise doing well clinically.

ULTRASONOGRAPHIC EXAMINATION OF THE ABDOMEN

Urinary System

The urinary bladder, trigone, cystourethral junction, and visible pelvic urethra exhibited normal thickness and tone. Anechoic urine was present in the lumen with no evidence of urine/lumen sediment, mineral, or calculi. The ureteral papillae were normal. The ureters were not visible which is normal. No evidence of inflammatory or neoplastic changes was noted.

Normal size and margination were present in the kidneys. A normal 1:3 cortex / medulla ratio was maintained. The medulla and cortices were uniform in texture with some increased echogenicity and mild loss of corticomedullary symmetry and definition expected for the age of the patient. No evidence of pelvic dilation was present. The left kidney measured 5.4 cm in length. The right kidney measured 5.9 cm in length.

The area of the aortic trifurcation was free of pathology.

Adrenal Glands

The left and right adrenal glands were not definitively visualized. No obvious pathology was present in the area of the bilateral adrenal glands.

Spleen

The spleen exhibited a finely textured and homogenous parenchyma which was hyperechoic to the liver and renal cortical parenchyma. The capsule was smooth and regular without apparent expansion. The splenic vasculature at the hilus was normal in volume with no evidence of congestion or thrombosis. Acute to chronic inflammatory, neoplastic, or benign parenchyma changes were not noted.

Liver/Gallbladder

The liver was subjectively normal in size, structure, and contour. The liver parenchyma was uniform and hypoechoic to the spleen with a mild coarse echotexture. Normal vascular volume. The hepatic and portal vasculature were normal in appearance without signs of congestion. The gallbladder was non-distended in size with thin walls and primarily anechoic luminal content. The cystic and common bile ducts were normal.

Gastrointestinal

The stomach presented intact wall layering with a normal wall layer ratio. The lumen of the stomach contained mild non-shadowing ingesta sonographically suggestive of food echogenicity with no signs of ileus, obstruction or foreign material.



PATIENT

Sparky Helliwell

SPECIES

Canine

BREED

Border Collie Mix

SEX

MN

AGE

10yr

WEIGHT

42.5

INTERPRETED BY

R. McKenzie Daniel,
DVM, DABVP
(Canine and Feline)

IMAGING PERFORMED BY

Sarah Green

HOSPITAL NAME

Healing Spirit Animal
Wellness

REFERRING VET

Sarah Green

INVOICE

24583

DATE

04/22/2026

The small intestine presented intact wall layering with 1:3 muscularis/mucosa ratio. The lumen of the small intestine contained segmental similar appearing non-shadowing ingesta/chyme with no signs of mechanical/metabolic ileus, obstruction or foreign material.

Normal visible colon wall layers were present with formed to semi formed feces in lumen.

Pancreas

The parenchyma of the left limb, body and right limb of the pancreas presented isoechoic to the adjacent omental fat. A normal curvilinear capsule contour of the pancreas was present. The visible pancreatic duct was normal. No signs of active inflammation or neoplastic disease was evident.

Free Abdomen

No omental masses, overt lymphadenopathy or peritoneal effusion was present.

ULTRASONOGRAPHIC FINDINGS

Primary

- Sonographically unremarkable gastrointestinal tract.
- Mild age-related renal changes.

INTERPRETATION OF THE FINDINGS & FURTHER RECOMMENDATIONS

No evidence of visceral pathology specifically, no evidence of recurrent gastrointestinal neoplasia or evidence of metastasis.

Sonographic monitoring based on clinical signs or oncology recommendations is suggested.



PATIENT

Sparky Helliwell

SPECIES

Canine

BREED

Border Collie Mix

SEX

MN

AGE

10yr

WEIGHT

42.5

INTERPRETED BY

R. McKenzie Daniel,
DVM, DABVP
(Canine and Feline)

IMAGING PERFORMED BY

Sarah Green

HOSPITAL NAME

Healing Spirit Animal
Wellness

REFERRING VET

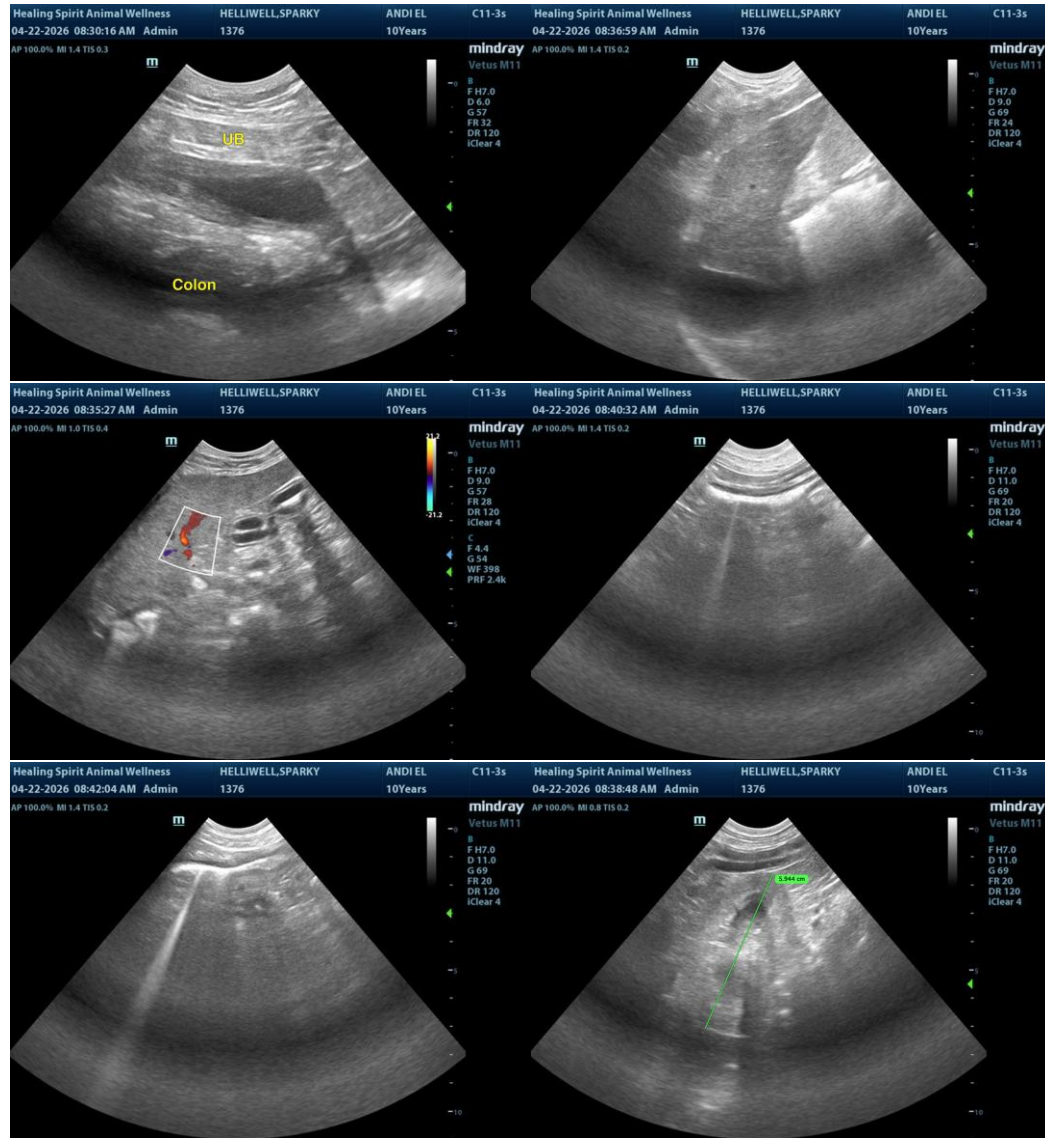
Sarah Green

INVOICE

24583

DATE

04/22/2026





PATIENT

Sparky Helliwell

SPECIES

Canine

BREED

Border Collie Mix

SEX

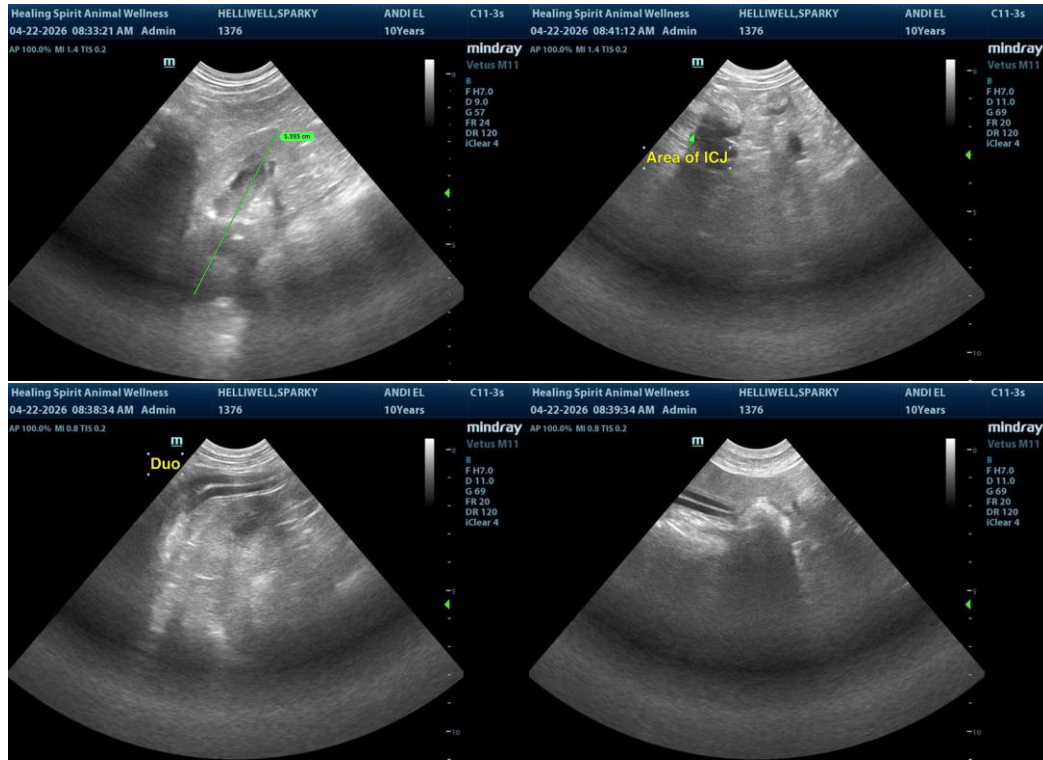
MN

AGE

10yr

WEIGHT

42.5



INTERPRETED BY

R. McKenzie Daniel,
DVM, DABVP
(Canine and Feline)

IMAGING PERFORMED BY

Sarah Green

HOSPITAL NAME

Healing Spirit Animal
Wellness

REFERRING VET

Sarah Green

INVOICE

24583

DATE

04/22/2026

The information and recommendations provided are based on the images presented by the referring veterinarian/sonographer. No evaluation can be communicated regarding pathology that was not visible in the image/video clips provided.

Thank you for this referral. If the clinical or image interpretation does not parallel your findings or if I can be of any further assistance, please contact me.

R. McKenzie Daniel, DVM, DABVP (Canine/Feline Practice)
info@sonopath.com